

Managing Carious Lesions: Consensus Recommendations on Carious Tissue Removal

Advances in Dental Research
2016, Vol. 28(2) 58–67
© International & American Associations
for Dental Research 2016
Reprints and permissions:
sagepub.com/journalsPermissions.nav
DOI: 10.1177/0022034516639271
adr.sagepub.com

F. Schwendicke¹, J.E. Frencen², L. Bjørndal³, M. Maltz⁴, D.J. Manton⁵,
D. Ricketts⁶, K. Van Landuyt⁷, A. Banerjee⁸, G. Campus⁹, S. Doméjean¹⁰,
M. Fontana¹¹, S. Leal¹², E. Lo¹³, V. Machiulskiene¹⁴, A. Schulte¹⁵, C. Splieth¹⁶,
A.F. Zandona¹⁷, and N.P.T. Innes¹⁸

Abstract

The International Caries Consensus Collaboration undertook a consensus process and here presents clinical recommendations for carious tissue removal and managing cavitated carious lesions, including restoration, based on texture of demineralized dentine. Dentists should manage the disease dental caries and control activity of existing cavitated lesions to preserve hard tissues and retain teeth long-term. Entering the restorative cycle should be avoided as far as possible. Controlling the disease in cavitated carious lesions should be attempted using methods which are aimed at biofilm removal or control first. Only when cavitated carious lesions either are noncleansable or can no longer be sealed are restorative interventions indicated. When a restoration is indicated, the priorities are as follows: preserving healthy and remineralizable tissue, achieving a restorative seal, maintaining pulpal health, and maximizing restoration success. Carious tissue is removed purely to create conditions for long-lasting restorations. Bacterially contaminated or demineralized tissues close to the pulp do not need to be removed. In deeper lesions in teeth with sensible (vital) pulps, preserving pulpal health should be prioritized, while in shallow or moderately deep lesions, restoration longevity becomes more important. For teeth with shallow or moderately deep cavitated lesions, carious tissue removal is performed according to *selective removal to firm dentine*. In deep cavitated lesions in primary or permanent teeth, *selective removal to soft dentine* should be performed, although in permanent teeth, *stepwise removal* is an option. The evidence and, therefore, these recommendations support less invasive carious lesion management, delaying entry to, and slowing down, the restorative cycle by preserving tooth tissue and retaining teeth long-term.

Keywords: dental caries, stepwise excavation, selective excavation, incomplete excavation, caries sealing, minimally invasive dentistry

¹Department of Operative and Preventive Dentistry, Charité—Universitätsmedizin Berlin, Berlin, Germany

²Department of Oral Function and Prosthetic Dentistry, College of Dental Sciences, Radboud University Medical Center, Nijmegen, The Netherlands

³Department of Cariology and Endodontics, Faculty of Health and Medical Sciences, University of Copenhagen, Copenhagen, Denmark

⁴Department of Preventive and Social Dentistry, Faculty of Odontology, Federal University of Rio Grande do Sul, Porto Alegre, Brazil

⁵Melbourne Dental School, University of Melbourne, Melbourne, Australia

⁶Section of Operative Dentistry, Fixed Prosthodontics and Endodontology, Dundee Dental Hospital and School, University of Dundee, Dundee, UK

⁷KULeuven BIOMAT, Department of Oral Health Sciences, University of Leuven and Dentistry University Hospitals Leuven, Leuven, Belgium

⁸Conservative and MI Dentistry, King's College London Dental Institute, London, UK

⁹Department of Surgery, Microsurgery and Medicine Sciences, School of Dentistry, University of Sassari, Italy; WHO Collaborating Centre for Epidemiology and Community Dentistry, University of Milan, Milan, Italy

¹⁰CHU Clermont-Ferrand, Service d'Odontologie, Hôtel-Dieu, Clermont-Ferrand, France; Univ Clermont I, UFR d'Odontologie, Clermont-Ferrand, France; Centre de Recherche en Odontologie Clinique EA 4847, F-63000 Clermont-Ferrand, France

¹¹Department of Cariology, Restorative Sciences and Endodontics, School of Dentistry, University of Michigan, Ann Arbor, MI, USA

¹²Department of Dentistry, Faculty of Health Sciences, University of Brasília, Brasília, Brazil

¹³Faculty of Dentistry, University of Hong Kong, Hong Kong, China

¹⁴Department of Dental and Oral Pathology, Faculty of Odontology, Lithuanian University of Health Sciences, Kaunas, Lithuania

¹⁵Department of Special Care Dentistry, Faculty of Health, University of Witten/Herdecke, Witten, Germany

¹⁶Preventive and Pediatric Dentistry, University of Greifswald, Greifswald, Germany

¹⁷Department of Operative Dentistry, University of North Carolina at Chapel Hill School of Dentistry, Chapel Hill, NC, USA

¹⁸Paediatric Dentistry, Dundee Dental Hospital and School, University of Dundee, Dundee, UK

Corresponding Author:

F. Schwendicke, Department of Operative and Preventive Dentistry, Charité—Universitätsmedizin Berlin, Aßmannshäuser Str. 4-6, 14197 Berlin.
Email: falk.schwendicke@charite.de

Introduction

This consensus paper is a report from the International Caries Consensus Collaboration (ICCC) meeting, held in Leuven, Belgium, in February 2015, comprising 21 experts in cariology from 12 countries covering North and South America, Europe, and Australasia. The ICCC group compiled expert consensus on terminology and recommendations for dealing with carious tooth tissue removal and managing cavitated carious lesions.

The background to this consensus collaboration meeting is the ongoing debate surrounding strategies for removing carious tissue, the growing number of studies and their synthesis into systematic reviews questioning conventional carious tissue removal, and the confusion around terms that refer to these strategies. Recommendations on managing dental caries are often related to specific stages of carious lesion extension—namely, the enamel lesion, the cavitated dentine lesion, or the lesion reaching the pulp. While it might be practical to separate the various stages of pathology for investigative and descriptive purposes, this separation results in isolated scientific “circles” where different views of treatment and names of concepts exist. Thus, there is a need for consensus, both on terminology (Innes et al. 2016) and on clinical recommendation regarding management of cavitated carious lesions. Consensus on these recommendations was reached after assessment of compiled and appraised evidence and through discussion. The strength of clinical recommendations was derived from this evidence and discussion and classified as being for or against an intervention, with further separation of weak and strong recommendations.

This report lays out the ICCC group’s clinical recommendations for carious tissue removal and cavity management, including restoration. The focus is on carious teeth that could be retained and with pulps responding positively to sensitivity testing (called “sensible pulps” for ease of communication in this paper) or those with reversible pulpitis (i.e., pulps with the ability to heal). There is an overview of the management of dental caries and carious lesions, defining and justifying thresholds for each management strategy. Next, carious tissue removal is discussed, and management options are detailed for lesions requiring a restoration with different strategies. For each of these issues, clinical recommendations are presented, and areas are identified where deeper or broader evidence are still needed. Finally, clinical recommendations and knowledge gaps are summarized.

Managing Dental Caries and Carious Lesions

What Is Dental Caries?

Dental caries is the name of a disease resulting from an ecologic shift within the dental biofilm, from a balanced population of microorganisms to an acidogenic, aciduric, and cariogenic microbiological population developed and maintained by frequent consumption of fermentable dietary carbohydrates. The resulting activity shift in the biofilm is associated with an imbalance between demineralization and remineralization,

leading to net mineral loss within dental hard tissues, the sign and symptom being a carious lesion (Fejerskov et al. 2015).

Consequently, dental caries is not an infectious disease that needs be “cured” by removing bacteria or, even less so, a particular bacterial species. Instead, dental caries can be managed behaviorally by controlling its causative factors—namely, the supply of fermentable carbohydrates and the presence and maturation of bacterial dental biofilms. If, however, such management is neither provided nor adhered to by the patient (i.e., the lesion activity is not controlled), the remaining cariogenic biofilm promotes progression of the lesion, which may eventually lead to both chronic pulp inflammation and the irreversible stages of pulp necrosis and apical periodontitis following bacterial penetration into the pulp cavity (Bjørndal and Rieucchi 2014).

How Should We Manage Dental Caries and Carious Lesions?

The tenets of minimal intervention dentistry (Frencken, Peters, et al. 2012; Banerjee and Doméjean 2013) allow dentists to pursue holistic and cause-based management of the disease “dental caries,” with the aim of maintaining healthy functional teeth for life. Effective management of the disease caries is characterized by detection of early lesions and subsequent accurate diagnosis, by caries activity and risk assessment, and by preventing occurrence of new carious lesions. The management of cavitated carious lesions focuses on arresting or controlling (including restoring) existing lesions through minimal invasive restorative treatments (evidence informed), including repairing rather than replacing defective restorations.

Given the pathologic basis for dental caries as a biofilm disease, both prevention of new lesions and management of existing lesions should focus primarily on control or management rather than tissue removal. For existing carious lesions, different lesion stages and activities might require different management, all of which should aim toward

- inactivation/control of the disease process,
- preservation of dental hard tissue,
- avoidance of initiating the cycle of reresoration, and
- preservation of the tooth for as long as possible.

The decision around when to use which management strategy should follow a rational pathway (as described here), with the most important question being “When do I need to intervene restoratively (invasively)?”

Noncavitated (i.e., cleansable) lesions can be managed with biofilm removal (toothbrushing) and/or remineralization or by sealing over them. In the case of occlusal lesions, this will be through placement of fissure sealants (Griffin et al. 2008; Hilgert et al. 2015) but in the case of proximal or smooth surfaces with pits, this will involve other methods of sealing or lesion infiltration with resin (Dorri et al. 2016). Cavitated dentine carious lesions that are accessible to visual-tactile inspection and activity evaluation are potentially cleansable lesions (i.e., assessed as being cleansable by the patient). These can be inactivated—that is, not require further treatment, as their progression is unlikely

and can be managed nonrestoratively (noninvasively; i.e., via biofilm removal or remineralization). Lesions that are not cleansable are likely to be active and progress but might be transformed into cleansable lesions by widening the opening and by encouraging effective oral hygiene practices in the individual, including fluoridated toothpaste and healthy dietary practices (*nonrestorative cavity control*). This is more widely performed in the primary dentition (Lo et al. 1998; Gruythuysen 2010; Mijan et al. 2014).

The line between a cleansable and noncleansable lesion is not a clear one, but this is an important point because when surface cavitation has occurred, lesions should be considered to be noncleansable and active until proven otherwise. Occlusal lesions can be assessed visually, but whether or not the surface is cavitated is not always clear. For proximal lesions, it can be even more difficult to carry out a clear visual-tactile evaluation. Tooth separation may be useful for direct visualization, and radiographs and fiber-optic transillumination can be valuable adjuncts but do not always lead to a definitive diagnosis on surface cavitation (Bader et al. 2001; Mialhe et al. 2009; Baclum et al. 2012). Other factors, including the patient's caries risk and the lesion's depth radiographically, should be considered in the decision regarding whether proximal surface cavitation is likely and whether the lesion is therefore noncleansable. The number of bacteria within the lesion increases as the lesion extends into dentine. Lesions with a surface breach that is not clearly detectable to the naked eye progress to clearly cavitated lesions (Ricketts et al. 1995; Ricketts et al. 1997). Sometimes the stage at which a surface breach has taken place but is not considered to be a frankly cavitated lesion is called *microcavitation*. This term is not agreed on and seems to mean different things—from a breach in the enamel that is not clearly detectable to the naked eye to being defined as when a community periodontal index of treatment needs (CPITN) probe will drop into a breach in the enamel. Preventing lesions with a surface breach from progressing might be difficult using biofilm removal and/or remineralization (Fusayama and Kurosaki 1972; Ricketts et al. 1997; Munson et al. 2004), but sealing over them and depriving the bacteria within the lesion of carbohydrates might arrest them (Griffin et al. 2008; Oong et al. 2008). Just as there is no clear line between cleansable and noncleansable, there is no clear line between a microcavitation that can be fissure sealed and when the breach becomes frank cavitation and may require restoration. The mechanical demands required of sealing materials increase with the size of the cavitation, which limits the options for sealing clearly cavitated lesions. A decision has to be made, with all tooth and patient factors in mind, regarding when either a sealant or a restoration that seals the carious lesion into the tooth might be required.

In summary, there are a variety of options for managing the disease or managing carious lesions nonrestoratively (noninvasively). However, for certain lesion stages or under certain conditions, restorative interventions are unavoidable. To allow practical implementation of these recommendations, the group has defined cutoffs to aid the decision on when to intervene restoratively. The consensus that emerged was as follows:

- Noncleansable cavitated dentine carious lesions cannot be managed by biofilm removal, remineralization, or sealing alone. However, in the primary dentition, these lesions might be transformable into cleansable lesions and managed via *nonrestorative cavity control*.
- Certain occlusal lesions might appear clinically noncavitated but radiographically extend significantly into dentine. If such lesions cannot be arrested through biofilm control alone, fissure sealing can be carried out; however, the integrity of the sealant needs to be monitored, and there is a possibility, until more evidence has emerged, that a "trampoline" effect may lead to failure of the sealant and a restoration will be required.

Recommendations. We have not made more detailed recommendations for managing noncavitated lesions, as this was not the focus of this meeting of the collaboration. Similarly, options such as sealing over lesions and the Hall technique have not been discussed extensively, as they do not require carious tissue removal.

1. Preventing carious lesions from occurring means managing the disease dental caries. For existing carious lesions, dentists should work with the patient to manage the disease and, as a consequence, to control the lesion activity—that is, aiming for lesion arrest/inactivation to preserve dental hard tissues, avoid initiation of the restorative cycle (Elderton 1993; Qvist 2015), and retain the tooth for as long as possible (strong recommendation).
2. When cavitated carious lesions are noncleansable and sealing is no longer an option, restorative interventions are indicated (strong recommendation).

Restorative Management of Carious Lesions

Why Do We Restore Teeth?

The aims of restorative management are to:

1. aid plaque control and thereby manage caries activity at this specific location;
2. protect the pulp-dentine complex and arrest the lesion by sealing it; and
3. restore the function, form, and aesthetics of the tooth (Kidd 2004).

Restorative management conventionally involves carious tissue removal, and the reasons for this have historically included the following:

- Withstand packing of materials and retain the restoration
This applies only to dental amalgam. When using adhesive materials, removal of dental hard tissues for this purpose cannot be justified.

- Remove bacteria

Given the pathology of dental caries and the effects of a tight seal on the viability of remaining bacteria with the biodiversity and cariogenicity of the remaining biofilm, tissue removal simply to remove bacteria is not logical or justified (Going et al. 1978; Banerjee et al. 2002; Paddick et al. 2005). It is currently not completely understood whether remaining bacteria or their metabolites have any detrimental effect on the pulp on subclinical level. However, the number of viable long-term remaining bacteria in proximity to the pulp does not seem to be increased in sealed lesions (Paddick et al. 2005) or when compared with traditionally treated carious lesions (Maltz, Henz, et al. 2012), and clinical studies have consequently not found detrimental effects to the pulp by sealing in bacteria (Ricketts et al. 2013).

- Remove demineralized dentine

Demineralized but structurally intact dentine that can be remineralized (Ogawa et al. 1983; Ngo et al. 2006) should be preserved. Some studies have even reported remineralization of infected disorganized dentine (Wambier et al. 2007; Chibinski et al. 2013; Corralo and Maltz 2013). In any case, clinical discrimination between these layers is difficult (see below).

In conclusion, the only evidence-based reason why removal of carious tissue is carried out today is to create a sufficiently large surface to bond to and thus optimize the longevity of a restoration.

What Guiding Principles Should Be Used during Removal of Carious Tissue?

The guiding principles for the removal of carious tissue are as follows:

- Preserve nondemineralized and remineralizable tissue
- Achieve an adequate seal by placing the peripheral restoration onto sound dentine and/or enamel, thus controlling the lesion and inactivating remaining bacteria
- Avoid discomfort/pain and dental anxiety, as both significantly influence treatment/care planning and outcomes (methods that are less likely to lead to dental anxiety are preferable)
- Maintain pulpal health by preserving residual dentine (avoiding unnecessary pulpal irritation/insult) and preventing pulp exposure (i.e., leave soft dentine in proximity to the pulp if required)

Avoiding pulpal exposure has great impact on the lifetime prognosis of the tooth and long-term treatment costs (Whitworth et al. 2005; Bjørndal et al. 2010; Schwendicke, Stolpe, et al. 2013). The thickness of residual dentine cannot be assessed clinically, but its preservation has been found to be a significant factor in avoiding pulpal distress (Smith et al. 2001; Whitworth et al. 2005). In deep lesions, preservation of residual dentine thickness is more likely when softer, bacteria-containing dentine is left over the pulpal aspect of the cavity instead of being removed.

- Maximize longevity of the restoration by removing enough soft dentine to place a durable restoration of sufficient bulk and resilience

With teeth that have sensible (vital) pulps that are free from pathologic signs and symptoms, these last 2 aims—maintaining pulpal health and maximizing restoration longevity—might need to be balanced against each other. In deep lesions (radiographically involving the inner pulpal third or quarter of dentine or with clinically assessed risk of pulpal exposure), preservation of pulpal health should be prioritized. In shallow or moderately deep lesions (those not reaching the inner third or quarter of the dentine), restoration longevity might be more important.

There are significant doubts around the validity of methods for assessing pulpal sensibility and pulpal health (Mejäre et al. 2012). However, when the chance of preserving pulpal health is weighed against the potential disadvantages of pulpal necrosis and infection associated with delaying endodontic therapy (potentially decreased prognosis compared with root canal therapy of vital pulps), current evidence indicates that maintaining pulpal health might be prioritized (Schwendicke and Stolpe 2014).

Recommendations

3. Restorative treatments are carried out to aid biofilm control; protect the pulp-dentine complex; and restore the function, form, and aesthetics of the tooth, while causing no unnecessary harm. The carious tissue removal stage aims to create conditions for a long-lasting restoration, preserve healthy and remineralizable tissue, achieve a sufficient seal, maintain pulpal health, and maximize success of the restoration. However, this does not necessarily mean that close to the pulp, all bacterially contaminated or demineralized tissues need to be removed (strong recommendation).
4. In deeper lesions in teeth with pulps that are sensible (vital), preserving pulpal health should be prioritized, while in shallow or moderately deep lesions, restoration longevity might be more important factor (strong recommendation).

How Should We Remove Carious Tissue in Teeth with Sensible, Asymptomatic Pulps?

To remove carious tissue in teeth with sensible (vital) pulps and no symptomatic/irreversible pulpitis, 5 main strategies are available that are based on the level of hardness of the remaining dentine (Ricketts et al. 2013). The decision among these strategies will be guided by the lesion depth and the dentition (Fig.).

Nonselective removal to hard dentine (formerly *complete excavation* or *complete caries removal*) uses the same criterion in assessing the end point of carious tissue removal for all parts of the cavity (i.e., peripherally and pulpally). Only hard dentine is left so that demineralized dentine “free” of bacteria is completely removed. This is considered overtreatment and no longer advocated.

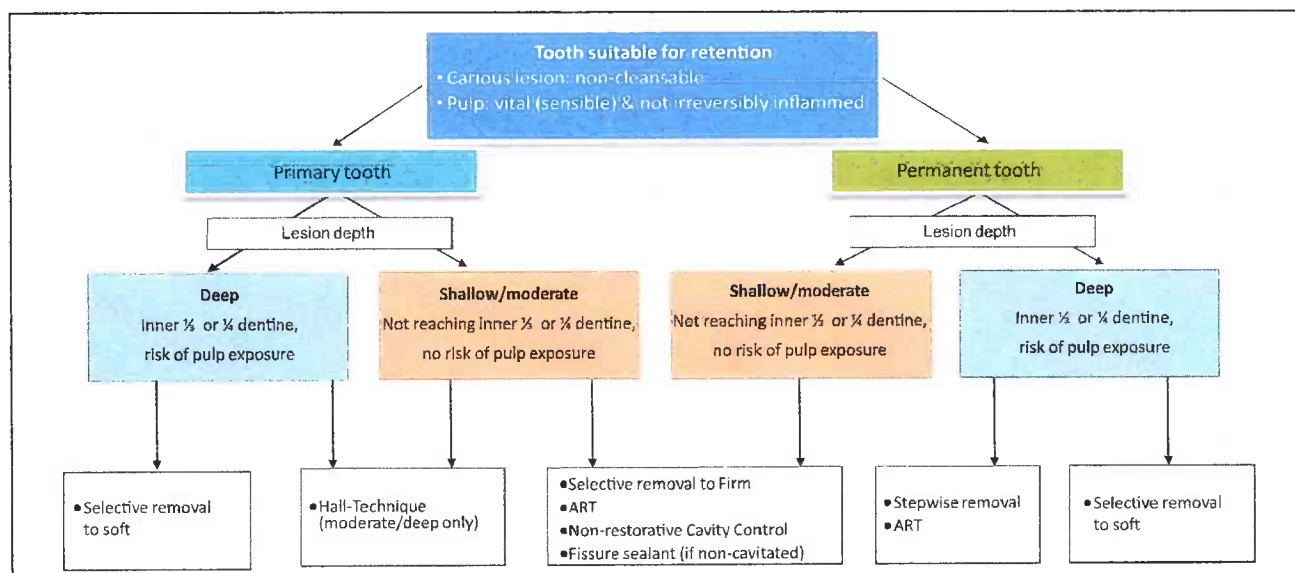


Figure. Decision making for noncleansable carious lesions in retainable teeth with vital pulps. ART, atraumatic restorative treatment.

Selective removal to firm dentine leaves “leathery” dentine pulpally; there is a feeling of resistance to a hand excavator while the cavity margins (i.e., peripheral dentine) are left hard (scratchy) after removal. *Selective removal to firm dentine* is the treatment of choice for both dentitions—in shallow or moderately deep cavitated dentinal lesions (i.e., lesions radiographically extending less than the pulpal third or quarter of dentine). In deeper lesions, selective removal to firm dentine bears significant risks for the pulp, which is why other strategies should be considered.

Selective removal to soft dentine is recommended in deep cavitated lesions (i.e., extending into the pulpal third or quarter of the dentine). Soft carious tissue is left over the pulp to avoid exposure and “stress” to the pulp, thereby promoting pulpal health, while peripheral enamel and dentine are prepared to hard dentine, to allow a tight seal and placement of a durable restoration. Selective removal to soft dentine reduces the risk of pulpal exposure significantly as compared with nonselective removal to hard or selective removal to firm dentine.

Stepwise removal is carious tissue removal in 2 stages, i.e., visits (Bjørndal et al. 1997; Bjørndal and Larsen 2000; Paddick et al. 2005). Soft carious tissue is left over the pulp in the first step, while peripheral dentine is prepared to hard dentine to allow a complete and durable seal of the lesion. A provisional restoration is placed, which should be sufficiently durable to last up to 12 mo to allow changes in the dentine and pulp to take place, also because patients may not return to complete the treatment (Maltz, Garcia, et al. 2012). The reasoning for stepwise removal is the expectation that in the first step, tertiary dentine is formed, demineralized dentin becomes remineralized, and the amount of viable bacteria is reduced. In reentering, the restoration is removed, and there is an opportunity to reevaluate changes in intralesion color and hardness. A calibrated color classification scale may also be used to gauge changes in the cariogenic environment (Bjørndal et al. 1997; Orhan et al. 2008; Bjørndal et al.

2014; Petrou et al. 2014). Drier lesions can also indicate less activity (Kidd et al. 1993). Carious tissue removal is continued only until “leathery” dentine remains over the pulp. There is some evidence that in such deep lesions, the second removal step may be omitted, as it increases risks of pulpal exposure and is thus detrimental to pulpal health (Maltz, Garcia, et al. 2012; Ricketts et al. 2013; Schwendicke, Meyer-Lückel, et al. 2013). The second step also adds additional cost, time, and discomfort to the patient. In the primary dentition, teeth have a limited life span, so stepwise removal is not considered necessary for primary teeth, and selective removal to soft dentine should be carried out.

Recommendations. Recommendations for removal of carious tissue apply only to teeth where restorative interventions are deemed unavoidable:

5. For teeth with shallow or moderately deep lesions, selective removal to firm dentine should be carried out (weak recommendation).
6. In deep lesions (radiographically extending into pulpal third or quarter of the dentine) in primary and permanent teeth, selective removal to soft dentine should be performed (strong recommendation).
7. In permanent teeth, stepwise removal might also be an option for deep lesions (strong recommendation).

How Should We Assess Removal of Carious Tissue?

To assess carious tissue removal, a variety of criteria have been suggested, including hardness, moisture, color, fluorescence properties, and dye stainability. Furthermore, carious tissue removal methods have been developed that attempt to define this end point (e.g., self-limiting burs, chemomechanical removal). Most of these have been validated in vitro but lack sufficient clinical validation, while some of them are even

detrimental, e.g., stainability via caries detector dyes (Schwendicke et al. 2014).

All described criteria for assessing or describing the dentine remaining after carious tissue removal are surrogate measures. These need to be validated against relevant outcomes (pain, maintenance of pulpal health, retention of the tooth). Only surrogate measures associated with such outcomes should be used by dentists during clinical assessment. As described in a previous section (How to Remove Carious Tissue in Teeth with Sensible, Asymptomatic Pulp?), harder, darker, and drier dentine reflects lesion arrest (Kidd et al. 1993; Bjørndal et al. 1997; Orhan et al. 2010; Petrou et al. 2014).

Recommendations

8. Hardness (e.g., soft, leathery, firm or scratchy, or hard) dentine should be the primary criterion for assessing, describing, and reporting on carious tissue and their removal (weak recommendation).
9. Moisture (wet, moist, or dry), color (pale/yellow, dark brown/black), and additional optical characteristics of dentine or measures of different bacterial metabolic products might be useful as additional indicators (weak recommendation).

How Should We Perform Carious Tissue Removal?

There are a large number of methods for carious tissue removal, including hand excavators, tungsten carbide burs, ceramic burs, air abrasion, sonoabrasion, chemomechanical carious tissue removal, polymer burs, and lasers. Most of these are also used to define an end point for carious tissue removal (see above); however, the end points have been validated only to a limited extent (Banerjee et al. 2000; Boston 2003; Celiberti et al. 2006; Neves Ade et al. 2011). As a result, information on clinical advantages or disadvantages of different excavation methods is sparse, with weak evidence finding hand or chemomechanical excavation potentially advantageous (Frencken, Peters, et al. 2012), although this is stronger for patient-reported outcomes such as pain and discomfort during removal, especially when undertaken by generalists (Rahimtoola et al. 2000; Nadanovsky et al. 2001; Rafique et al. 2003; Schriks and van Amerongen 2003; de Menezes Abreu et al. 2011).

Recommendations

10. There is insufficient evidence to recommend any single method for carious tissue removal. Hand or chemomechanical excavation might reduce pain and discomfort during treatment and could thus positively affect dental anxiety, especially when treating children (weak recommendation).

How Should We Manage the Resulting Cavity?

Various steps, such as cavity disinfection and cavity lining, have been traditionally carried out after removal of carious tissue but before restoration of the cavity.

Cavity disinfection has been advocated to reduce the number of remaining bacteria. Given that the number of bacteria might be of limited importance if a tight restorative seal has been achieved and that the effects of disinfection methods might be limited to superficial dentine only, the concepts underlying this procedure are likely to be theoretically flawed and could unnecessarily increase treatment time and cost. There is insufficient evidence to support cavity disinfection. Additional putative benefits, such as chlorhexidine application and stannous fluoride, to inactivate dentinal matrix metalloproteinase or remineralize dentine, have not yet been sufficiently substantiated through clinical trials (Frag et al. 2009).

Cavity lining has been traditionally used in treating deep carious lesions (most commonly calcium hydroxide) to reduce the number of residual viable bacteria, remineralize dentine, induce reactionary dentine, isolate the pulp, and protect pulpal cells from noxious stimuli (About et al. 2001). As already discussed, reducing bacterial numbers might not be relevant if cavity sealing is achieved, and current evidence regarding the antibacterial effects of different dental materials is ambiguous (Schwendicke et al. 2015; do Amaral et al. 2016). Remineralization of remaining demineralized dentine seems to be mediated by pulpal activities and might not require separate liners (Corralo and Maltz 2013). Although certain liners seem capable of inducing dentinogenesis and reducing pulpal inflammation (Fusayama 1997), the evidence is sparse and the clinical relevance unclear (Hebling et al. 1999; Schwendicke, Meyer-Lückel, et al. 2013; Dalpian et al. 2014). With the advent of new materials, such as calcium silicates, and clinical studies investigating these, evidence of patient benefit may emerge (Hashem et al. 2015).

The isolation of the pulp against thermal insult is relevant in placing thermally conducting material (dental amalgam). Isolating the pulp when placing resin restorations might be beneficial, as monomers penetrate through dentine into the pulp (Galler et al. 2005; Modena et al. 2009). In addition, the expected effects of liners might depend on which removal strategy for carious tissue is performed. Caries-affected dentine has a lower elastic modulus and is intrinsically less resistant to tensile forces; it may thus not be able to withstand shrinkage forces during bonding, thereby leading to fracture lines within the dentine that may facilitate pulp damage (Perdigão 2010; Tjäderhane 2015).

Recommendations

11. Cavity disinfection procedures currently have no evidence of patient benefit to support their use (weak recommendation).
12. Placement of cavity-lining materials are not necessary to control the sealed lesion but might be beneficial in impeding monomer penetration and avoidance of fracture of the remaining dentine when resin composite is the restorative material (weak recommendation).

How Should We Restore the Cavity?

Once the decision has been made to manage a carious lesion with a restoration, it must be of the highest possible quality to guarantee durability and avoid the need for replacement.

Of the various direct restorative materials available to restore cavities, dental amalgam has been historically accepted as the standard for restoration of carious lesions in posterior teeth. Although unaesthetic, amalgam restorations have good longevity and are especially successful in patients at high risk of caries (Opdam et al. 2010). This has been attributed to the corrosion products, which can seal the margin soon after placement, have antibacterial properties, and may protect against secondary carious lesions. However, for environmental reasons, many countries have committed themselves to phase down the use of amalgam, and the Minamata Treaty on Mercury was signed in October 2013 (United Nations Environmental Programme 2013).

Conversely, resin composite use has been increasing, with its longevity now being similar to amalgam restorations, although composites in patients at high caries risk seem more prone to secondary carious lesions (Opdam et al. 2010; Kopperud et al. 2012). The reasons for this are probably multifactorial and not yet well understood. Resin composites are bonded to dental hard tissue with adhesives. These adhesives have been increasingly optimized and are important to seal the resin composite restoration, withstand polymerization shrinkage forces, and ensure retention to the cavity walls when functionally loaded (De Munck et al. 2003). In vitro, when bond quality is quantitatively assessed via mechanical tests, such as tensile and shear bond strength tests, there is a correlation between the retention rate of cervical restorations and the bond strength (Van Meerbeek et al. 2010). However, in vitro tests used to assess the sealing ability of composite restorations seem to have little clinical significance (Heintze 2013). It is generally accepted that the bond to sound dental hard tissues is important to guarantee good sealing of the resin composite (De Munck et al. 2003). In spite of the formation of much thicker hybrid layers in carious dentine, immediate bond strengths have been found to be significantly lower than those to sound dentine (Yoshiyama et al. 2002). This has been attributed to the low elastic modulus and the increased wetness typical of carious dentine. Clinically, this does not seem to present a problem if only limited amounts of carious dentine are left beneath a restoration (Schwendicke, Meyer-Lückel, et al. 2013). Since bond strength is proportional to the area of the bonded surface, carious dentine that is left to preserve pulpal health should be limited to areas over the dental pulp in the cavity: it is especially important that the periphery of the cavity should support the restoration sufficiently and allow a tight seal.

The third main alternative is glass ionomer cement (GIC), which has been generally viewed, until recently, as a temporary/interim restorative material or that limited to use in primary teeth or when other materials cannot be used. This material has good biocompatibility, releases fluoride, and bonds chemically to dental hard tissues. However, as compared with resin composites, glass ionomers are less aesthetic and have higher "early" wear, and results from older and noncontrolled trials (Manhart et al. 2004) showed them to be prone to mechanical failure, particularly in large proximal occlusally loaded cavities. More recent systematic reviews have reported no difference in survival rates of high-viscosity GIC (when used in

atraumatic restorative treatment) and amalgam (Mickenautsch and Yengopal 2012) or resin composite restorations in children (Raggio et al. 2013). Overall, a growing body of evidence finds high-viscosity GIC a valuable alternative for primary teeth and in single-surface cavities in permanent teeth (Frencken, Leal, et al. 2012).

Apart from these materials, metal or ceramic indirect restorations (inlays, onlays, crowns) can be used. These, however, usually require more invasive tooth preparation, with sacrifice of additional sound tooth tissue, and are more expensive (Kelly and Smales 2004).

In assessing the performance of all materials, decisions around replacement or reintervention should still follow the guiding principles for restorative interventions. For example, detection of a radiolucency beneath a restoration where there is an intact seal and no pulpal symptoms would not warrant replacement of the restoration, and monitoring would be more suitable. Similarly, once the decision to reintervene has been made, sound tooth tissues should be preserved during replacement to preserve pulpal health, reduce costs, and limit the subjective burden to the patient. Thus, resealing, refurbishing, repolishing, and repairing restorations should be performed whenever possible and complete restoration replacement avoided (Green et al. 2015).

Recommendations

13. The choice of materials for restoring cavities should be guided by the location and extent of the lesion, the caries risk, the carious lesion activity, and the specific patient conditions and setting. There is no definitive evidence to support particular materials as more suitable than others for restoring teeth after selective carious tissue removal to soft or firm dentine (weak recommendation).
14. Retreatment of restorations should aim to repair by resealing, refurbishing, or repolishing where possible, and replacement should be a last resort (strong recommendation).

Recommendations and Knowledge Gaps

Clinical Recommendations

1. Preventing carious lesions from occurring means managing the disease dental caries. For existing carious lesions, dentists should work with the patient to manage the disease and, as a consequence, to control the lesion activity—aiming for lesion arrest/inactivation to preserve dental hard tissues, avoid initiation of the restorative cycle (Elderton 1993; Qvist 2015), and retain the tooth for as long as possible (strong recommendation).
2. When cavitated carious lesions are noncleansable and sealing is no longer an option, restorative interventions are indicated (strong recommendation).
3. Restorative treatments are carried out to aid biofilm control, protect the pulp-dentine complex, and restore the function, form, and aesthetics of the tooth, while

causing no unnecessary harm. The carious tissue removal stage aims to create conditions for a long-lasting restoration, preserve healthy and remineralizable tissue, achieve a sufficient seal, maintain pulpal health, and maximize success of the restoration. However, this does not necessarily mean that, close to the pulp, all bacterially contaminated or demineralized tissues need to be removed (strong recommendation).

4. In deeper lesions in teeth with still sensible (vital) pulps, preserving pulpal health should be prioritized over restoration success, while in shallow or moderately deep lesions, restoration longevity might be more important factor (strong recommendation).
5. For teeth with shallow or moderately deep lesions, selective removal to firm dentine should be carried out (weak recommendation).
6. In deep lesions (radiographically extending into pulpal third or quarter of the dentine) in primary and permanent teeth, selective removal to soft dentine should be performed (strong recommendation).
7. In permanent teeth, stepwise removal might also be an option for deep lesions (strong recommendation).
8. Hardness (e.g., soft, leathery, firm or scratchy, or hard) dentine should be the primary criterion for assessing, describing, and reporting on carious tissue and its removal (weak recommendation).
9. Moisture (wet, moist, dry), color (pale/yellow, dark brown/black), and additional optical characteristics of dentine or measures of different bacterial metabolic products might be useful as additional indicators (weak recommendation).
10. There is insufficient evidence to recommend any single method for carious tissue removal. Hand or chemomechanical excavation might reduce pain and discomfort during treatment and could thus have a positive impact on dental anxiety, especially when treating children (weak recommendation).
11. Cavity disinfection procedures currently have no evidence of patient benefit to support their use (weak recommendation).
12. Placement of cavity-lining materials are not necessary to control the sealed lesion but might be beneficial in impeding monomer penetration and avoidance of fracture of the remaining dentine when resin composite is the restorative material (weak recommendation).
13. The choice of materials for restoring cavities should be guided by the location and extent of the lesion, the caries risk, the carious lesion activity, and the specific patient conditions and setting. There is no definitive evidence to support particular materials as more suitable than others for restoring teeth after selective carious tissue removal to soft or firm dentine (weak recommendation).
14. Retreatment of restorations should aim to repair by resealing, refurbishing, or repolishing where possible, and replacement should be a last resort (strong recommendation).

Knowledge Gaps

15. Clinical trials investigating management of cavitated carious lesions should report full details, using agreed terms of
 - lesion depth, activity, and extent;
 - patients (caries risk and age), setting, and who carried out the treatment; and
 - how treatment was performed.

Journals should insist on this reporting and enforce use of appropriate terms (strong recommendation).

16. For trials investigating management of cavitated carious lesions in both clinical and laboratory settings, outcomes with sufficient validity and relevance to stakeholders, such as patients, dentists, and health care regulators/funders, should be used. If surrogate measures are used, these should be validated against such outcomes (strong recommendation).
17. Clinical trials should clearly report a primary outcome (on which the study is powered), seek long-term follow-up, report on events and harms in detail, and continue to follow-up teeth after any event, to allow judgment of the impact of different events on the described outcomes. Trials should be conducted with as high internal and external validity as possible. These should be interpreted with an understanding of where true risk of bias lies given the limitations—particularly in operator, participant, and assessor blinding in some study designs, as well as studies set in primary care and community settings. Limitations should be clearly expressed (strong recommendation).
18. Clinical trials should evaluate the combined effect of carious removal strategies and restorative procedures, including liners, adhesive strategies, and restorative materials, as different strategy combinations are expected to affect outcomes differently (strong recommendation).
19. Basic research should aim to answer the questions around the histologic and immunopathologic reaction of the pulp toward different carious tissue removal strategies, methods, and restorative procedures (strong recommendation).
20. Research efforts should endeavor to develop a method (or methods) that precisely and accurately ascertains pulpal health status in clinical settings (strong recommendation).

Author Contributions

F. Schwendicke, J. Frencen, N. Innes, contributed to conception, design, data acquisition, analysis, and interpretation, drafted and critically revised the manuscript; L. Bjørndal, M. Maltz, D.J. Manton, D. Ricketts, K. Van Landuyt, A. Banerjee, G. Campus, S. Doméjean, M. Fontana, S. Leal, E. Lo, V. Machiulskiene, A. Schulte, C. Splieth, A.F. Zandona, contributed to conception, design, data acquisition, analysis, and interpretation, critically revised the manuscript. All authors gave final approval and agree to be accountable for all aspects of the work.

Acknowledgments

ICCC thanks Lisbet Brike and Amy Caldwell-Nichols for organizing travel and accommodation for the conference in Leuven and to Amy Caldwell-Nichols for additional document and manuscript preparation support. Thank you also to GC for the use of its premises in Leuven. Grateful thanks also go to Professor Edwina Kidd, for her presentation, invaluable discussions at the meeting in Leuven, and her input into improving this manuscript and, finally, for so generously sharing her wisdom and experience. We thank Prof. W. Buchalla for his contribution to the meeting, and we respect his decision not to support the content of the manuscript. The conference was kindly sponsored by GC Europe (Leuven, Belgium), DMG (Hamburg, Germany), 3M Espe (Seefeld, Germany), and Dentsply DeTrey (Konstanz, Germany). The sponsors had no role in the design or conduct of the conference or the content of this manuscript and were not present during the conference. Travel to the meeting and accommodation for L.B., W.B., S.D., E.K., M.M., D.M., K.V.L., A.B., G.C., M.F., S.L., E.L., V.M., A.S., C.S., and A.Z. were supported by the sponsors. No honoraria were given to any of the participants. The corresponding author formally requested a declaration of possible conflicts of interest from each of the consensus conference members. For the purposes of transparency, we have listed a comprehensive declaration of interests: A.B.—commercial grant: GSK, 3MESPE, paid lectures: 3MESPE, GC, Septodont, Colgate, OralB; A.S.—none; A.Z.—paid lectures, ICDAS Foundation member; C.S.—none; D.M.—commercial grants: GC, paid lectures: GC, DMG; D.R.—none; E.L.—none; F.S.—commercial grant: DMG, GC, paid lectures and consultancy work: DMG; G.C.—none; J.F.—paid lectures: 3MESPE India and GC America; K.V.L.—none; L.B.—none; M.F.—none; M.M.—none; N.P.T.I.—commercial grant: 3MESPE (2001), paid lectures: 3MESPE, Colgate; S.D.—none; S.L.—paid lectures: GC; V.M.—none. The authors declare no other potential conflicts of interest with respect to the authorship and/or publication of this article.

References

- About I, Murray PE, Franquin JC, Remusat M, Smith AJ. 2001. The effect of cavity restoration variables on odontoblast cell numbers and dental repair. *J Dent*. 29(2):109–117.
- Bader JD, Shugars DA, Bonito AJ. 2001. Systematic reviews of selected dental caries diagnostic and management methods. *J Dent Educ*. 65(10):960–968.
- Baculum V, Hintze H, Wenzel A, Danielsen B, Nyvad B. 2012. Implications of caries diagnostic strategies for clinical management decisions. *Community Dent Oral Epidemiol*. 40(3):257–266.
- Banerjee A, Doméjean S. 2013. The contemporary approach to tooth preservation: minimum intervention (MI) caries management in general practice. *Prim Dent J*. 2(3):30–37.
- Banerjee A, Kidd EA, Watson TF. 2000. In vitro evaluation of five alternative methods of carious dentine excavation. *Caries Res*. 34(2):144–150.
- Banerjee A, Yasseri M, Munson M. 2002. A method for the detection and quantification of bacteria in human carious dentine using fluorescent *in situ* hybridisation. *J Dent*. 30(7–8):359–363.
- Bjørndal L, Demant S, Dabelsteen S. 2014. Depth and activity of carious lesions as indicators for the regenerative potential of dental pulp after intervention. *J Endod*. 40(4):76S–81S.
- Bjørndal L, Larsen T. 2000. Changes in the cultivable flora in deep carious lesions following a stepwise excavation procedure. *Caries Res*. 34(6):502–508.
- Bjørndal L, Larsen T, Thylstrup A. 1997. A clinical and microbiological study of deep carious lesions during stepwise excavation using long treatment intervals. *Caries Res*. 31(6):411–417.
- Bjørndal L, Reit C, Bruun G, Markvart M, Kjaeldgaard M, Näsman P, Thordrup M, Dige I, Nyvad B, Fransson H, et al. 2010. Treatment of deep caries lesions in adults: randomized clinical trials comparing stepwise vs. direct complete excavation, and direct pulp capping vs. partial pulpotomy. *Eur J Oral Sci*. 118(3):290–297.
- Bjørndal L, Rieucchi D. 2014. Pulp inflammation: from the reversible inflammation to pulp necrosis during caries progression. In: Michel Goldberg, editor. *The dental pulp biology, pathology, and regenerative therapies*. Berlin (Germany): Springer. p. 125–139.
- Boston DW. 2003. New device for selective dentin caries removal. *Quintessence Int*. 34(9):678–685.
- Celiberti P, Francescut P, Lussi A. 2006. Performance of four dentine excavation methods in deciduous teeth. *Caries Res*. 40(2):117–123.
- Chibinski AC, Reis A, Kreich EM, Tanaka JL, Wambier DS. 2013. Evaluation of primary carious dentin after cavity sealing in deep lesions: a 10- to 13-month follow-up. *Pediatr Dent*. 35(3):E107–E112.
- Corralo DJ, Maltz M. 2013. Clinical and ultrastructural effects of different liners/restorative materials on deep carious dentin: a randomized clinical trial. *Caries Res*. 47(3):243–250.
- Dalpián DM, Ardenghi TM, Demarco FF, Garcia-Godoy F, De Araujo FB, Casagrande L. 2014. Clinical and radiographic outcomes of partial caries removal restorations performed in primary teeth. *Am J Dent*. 27(2):68–72.
- de Menezes Abreu DM, Leal SC, Mulder J, Frencken JE. 2011. Pain experience after conventional, atraumatic, and ultraconservative restorative treatments in 6- to 7-year-old children. *Eur J Oral Sci*. 119(2):163–168.
- De Munck J, Van Meerbeek B, Yoshida Y, Inoue S, Vargas M, Suzuki K, Lambrechts P, Vanherle G. 2003. Four-year water degradation of total-etch adhesives bonded to dentin. *J Dent Res*. 82(2):136–140.
- do Amaral GS, de Cássia Negrini T, Maltz M, Arthur RA. 2016. Restorative materials containing antimicrobial agents: Is there evidence for their antimicrobial and anti-caries effects? A systematic-review. *Austr Dent J*. 61(1):6–15.
- Dorri M, Dunne SM, Walsh T, Schwendicke F. 2015. Micro-invasive interventions for managing proximal dental decay in primary and permanent teeth. *Cochrane Database Syst Rev*. 11:CD010431. doi:10.1002/14651858.CD010431.pub2
- Elderton RJ. 1993. Overtreatment with restorative dentistry: when to intervene? *Int Dent J*. 43(1):17–24.
- Farag A, van der Sanden WJ, Abdelwahab H, Mulder J, Frencken JE. 2009. 5-year survival of art restorations with and without cavity disinfection. *J Dent*. 37(6):468–474.
- Fejerskov O, Nyvad B, Kidd EA. 2015. Pathology of dental caries. In: Fejerskov O, Nyvad B, Kidd EAM, editors. *Dental caries: the disease and its clinical management*. 3rd ed. Oxford (UK): Wiley Blackwell. p. 7–9.
- Frencken JE, Leal SC, Navarro MF. 2012. Twenty-five-year atraumatic restorative treatment (ART) approach: a comprehensive overview. *Clin Oral Invest*. 16(5):1337–1346.
- Frencken JE, Peters MC, Manton DJ, Leal SC, Gordan VV, Eden E. 2012. Minimal intervention dentistry for managing dental caries—a review: report of a FDI task group. *Int Dent J*. 62(5):223–243.
- Fusayama T. 1997. The process and results of revolution in dental caries treatment. *Int Dent J*. 47(3):157–166.
- Fusayama T, Kurosaki N. 1972. Structure and removal of carious dentin. *Int Dent J*. 22(3):401–411.
- Galler K, Hiller KA, Ettl T, Schmalz G. 2005. Selective influence of dentin thickness upon cytotoxicity of dentin contacting materials. *J Endod*. 31(5):396–399.
- Going RE, Locsche WJ, Grainger DA, Syed SA. 1978. The viability of micro-organisms in carious lesions five years after covering with a fissure sealant. *J Am Dent Assoc*. 97(3):455–462.
- Green D, Mackenzie L, Banerjee A. 2015. Minimally invasive long term management of direct restorations: the “5rs.” *Dent Update*. 42(5):413–426.
- Griffin SO, Oong E, Kohn W, Vidakovic B, Gooch BF; CDC Dental Sealant Systematic Review Work Group, Bader J, Clarkson J, Fontana MR, Meyer DM, Rozier RG, Weintraub JA, Zero DT. 2008. The effectiveness of sealants in managing caries lesions. *J Dent Res*. 87(2):169–174.
- Gruythuysen R. 2010. Non-restorative cavity treatment: managing rather than masking caries activity. *Ned Tijdschr Tandheelkd*. 117(3):173–180.
- Hashem D, Mannocci F, Patel S, Manoharan A, Brown JE, Watson TF, Banerjee A. 2015. Clinical and radiographic assessment of the efficacy of calcium silicate indirect pulp capping: a randomized controlled clinical trial. *J Dent Res*. 94(4):562–568.
- Hebling J, Giro EM, Costa CA. 1999. Biocompatibility of an adhesive system applied to exposed human dental pulp. *J Endod*. 25(10):676–682.
- Heintze SD. 2013. Clinical relevance of tests on bond strength, microleakage and marginal adaptation. *Dent Mater*. 29(1):59–84.
- Hilgert L, Leal S, Mulder J, Creugers N, Frencken J. 2015. Caries-preventive effect of supervised toothbrushing and sealants. *J Dent Res*. 94(9):1218–1224.

- Innes NPT, Frencken JE, Bjørndal L, Maltz M, Manton DJ, Ricketts D, Van Landuyt K, Banerjee A, Campus G, Doméjean S, et al. 2016. Managing carious lesions: consensus recommendations on terminology. *Adv Dent Res*. 28(2):49–57.
- Kelly PG, Smales RJ. 2004. Long-term cost-effectiveness of single indirect restorations in selected dental practices. *Br Dent J*. 196(10):639–643.
- Kidd EA. 2004. How “clean” must a cavity be before restoration? *Caries Res*. 38(3):305–313.
- Kidd EA, Joyston-Bechal S, Beighton D. 1993. Microbiological validation of assessments of caries activity during cavity preparation. *Caries Res*. 27(5):402–408.
- Kopperud SE, Tveit AB, Gaarden T, Sandvik L, Espelid I. 2012. Longevity of posterior dental restorations and reasons for failure. *Eur J Oral Sci*. 120(6):539–548.
- Lo EC, Schwarz E, Wong MC. 1998. Arresting dentine caries in Chinese pre-school children. *Int J Paed Dent*. 8(4):253–260.
- Maltz M, Garcia R, Jardim JJ, de Paula LM, Yamaguti PM, Moura MS, Garcia F, Nascimento C, Oliveira A, Mestrinho HD. 2012. Randomized trial of partial vs. stepwise caries removal: 3-year follow-up. *J Dent Res*. 91(11):1026–1031.
- Maltz M, Henz SL, de Oliveira EF, Jardim JJ. 2012. Conventional caries removal and sealed caries in permanent teeth: a microbiological evaluation. *J Dent*. 40(9):776–782.
- Manhart J, Chen HY, Hamm G, Hickel R. 2004. Review of the clinical survival of direct and indirect restorations in posterior teeth of the permanent dentition. *Oper Dent*. 29(5):481–508.
- Mejäre IA, Axelsson S, Davidson T, Frisk F, Hakeberg M, Kvist T, Norlund A, Petersson A, Portenier I, Sandberg H, et al. 2012. Diagnosis of the condition of the dental pulp: a systematic review. *Int Endod J*. 45(7):597–613.
- Mialhe FL, Pereira AC, Meneghim Mde C, Ambrosano GM, Pardi V. 2009. The relative diagnostic yields of clinical, foci and radiographic examinations for the detection of approximal caries in youngsters. *Indian J Dent Res*. 20(2):136–140.
- Mickenausch S, Yengopal V. 2012. Failure rate of high-viscosity gic based art compared with that of conventional amalgam restorations—evidence from an update of a systematic review. *SADJ*. 67(7):329–331.
- Mijan M, de Amorim RG, Leal SC, Mulder J, Oliveira L, Creugers NH, Frencken JE. 2014. The 3.5-year survival rates of primary molars treated according to three treatment protocols: a controlled clinical trial. *Clin Oral Invest*. 18(4):1061–1069.
- Modena KC, Casas-Apayco LC, Atta MT, Costa CA, Hebling J, Sipert CR, Navarro MF, Santos CF. 2009. Cytotoxicity and biocompatibility of direct and indirect pulp capping materials. *J Appl Oral Sci*. 17(6):544–554.
- Munson MA, Banerjee A, Watson TF, Wade WG. 2004. Molecular analysis of the microflora associated with dental caries. *J Clin Microbiol*. 42(7):3023–3029.
- Nadanovsky P, Cohen Carneiro F, Souza de Mello F. 2001. Removal of caries using only hand instruments: a comparison of mechanical and chemo-mechanical methods. *Caries Res*. 35(5):384–389.
- Neves Ade A, Coutinho E, De Munck J, Van Meerbeek B. 2011. Caries-removal effectiveness and minimal-invasiveness potential of caries-excitation techniques: a micro-CT investigation. *J Dent*. 39(2):154–162.
- Ngo HC, Mount G, McIntyre J, Tuisuva J, Von Doussa RJ. 2006. Chemical exchange between glass-ionomer restorations and residual carious dentine in permanent molars: An in vivo study. *J Dent*. 34(8):608–613.
- Ogawa K, Yamashita Y, Ichijo T, Fusayama T. 1983. The ultrastructure and hardness of the transparent layer of human carious dentin. *J Dent Res*. 62(1):7–10.
- Oong EM, Griffin SO, Kohn WG, Gooch BF, Caulfield PW. 2008. The effect of dental sealants on bacteria levels in caries lesions. *J Amer Dent Assoc*. 139(3):271–278.
- Opdam NJ, Bronkhorst EM, Loomans BA, Huysmans MC. 2010. 12-year survival of composite vs. amalgam restorations. *J Dent Res*. 89(10):1063–1067.
- Orhan A, Oz F, Ozcelik B, Orhan K. 2008. A clinical and microbiological comparative study of deep carious lesion treatment in deciduous and young permanent molars. *Clin Oral Invest*. 12(4):369–378.
- Orhan AI, Oz FT, Orhan K. 2010. Pulp exposure occurrence and outcomes after 1- or 2-visit indirect pulp therapy vs complete caries removal in primary and permanent molars. *Pediatr Dent*. 32(4):347–355.
- Paddick JS, Brailsford SR, Kidd EA, Beighton D. 2005. Phenotypic and genotypic selection of microbiota surviving under dental restorations. *Appl Environ Microbiol*. 71(5):2467–2472.
- Perdigão J. 2010. Dentin bonding—variables related to the clinical situation and the substrate treatment. *Dent Mater*. 26(2):e24–e37.
- Petrou M, Alhamoui F, Welk A, Altarabulsi M, Alkilzy M, Splieth CH. 2014. A randomized clinical trial on the use of medical Portland cement, MTA and calcium hydroxide in indirect pulp treatment. *Clin Oral Invest*. 18(5):1383–1389.
- Qvist V. 2015. Longevity of restorations: the “death spiral.” In: Fejerskov O, Kidd EAM, editors. *Dental caries: the disease and its clinical management*. 3rd ed. Oxford (UK): Blackwell Munksgaard. p. 388.
- Rafique S, Fiske J, Banerjee A. 2003. Clinical trial of an air-abrasion/chemomechanical operative procedure for the restorative treatment of dental patients. *Caries Res*. 37(5):360–364.
- Raggio DP, Hesse D, Lenzi TL, Guglielmi CA, Braga MM. 2013. Is atraumatic restorative treatment an option for restoring occlusoproximal caries lesions in primary teeth? A systematic review and meta-analysis. *Int J Paed Dent*. 23(6):435–443.
- Rahimtoola S, van Amerongen E, Maher R, Groen H. 2000. Pain related to different ways of minimal intervention in the treatment of small caries lesions. *ASDC J Dent Child*. 67(2):123–127, 183.
- Ricketts D, Kidd E, Weerheijm K, de Soet H. 1997. Hidden caries: what is it? Does it exist? Does it matter? *Int Dent J*. 47(5):259–265.
- Ricketts D, Lamont T, Innes NP, Kidd E, Clarkson JE. 2013. Operative caries management in adults and children. *Cochrane Database Syst Rev*. 28:CD003808.
- Ricketts DN, Kidd EA, Beighton D. 1995. Operative and microbiological validation of visual, radiographic and electronic diagnosis of occlusal caries in non-cavitated teeth judged to be in need of operative care. *Br Dent J*. 179(6):214–220.
- Schriks MC, van Amerongen WE. 2003. Atraumatic perspectives of art: psychological and physiological aspects of treatment with and without rotary instruments. *Community Dent Oral Epidemiol*. 31(1):15–20.
- Schwendicke F, Meyer-Lückel H, Dörfer C, Paris S. 2013. Failure of incompletely excavated teeth: a systematic review. *J Dent*. 41(7):569–580.
- Schwendicke F, Paris S, Tu Y. 2014. Effects of using different criteria and methods for caries removal: a systematic review and network meta-analysis. *J Dent*. 43(1):1–15.
- Schwendicke F, Stolpe M. 2014. Direct pulp capping after a carious exposure versus root canal treatment: a cost-effectiveness analysis. *J Endod*. 40(11):1764–1770.
- Schwendicke F, Stolpe M, Meyer-Lueckel H, Paris S, Dörfer CE. 2013b. Cost-effectiveness of one- and two-step incomplete and complete excavations. *J Dent Res*. 92(10):880–887.
- Schwendicke F, Tu YK, Hsu LY, Göstemeyer G. 2015. Antibacterial effects of cavity lining: a systematic review and network meta-analysis. *J Dent*. 43(11):1298–1307.
- Smith AJ, Murray PE, Sloan AJ, Matthews JB, Zhao S. 2001. Trans-dentinal stimulation of tertiary dentinogenesis. *Adv Dent Res*. 15:51–54.
- Tjäderhane L. 2015. Dentin bonding: can we make it last? *Oper Dent*. 40(1):4–18.
- United Nations Environmental Programme. 2013. Minamata convention on mercury. New York (NY): United Nations [accessed 25 Feb 2016]. <http://www.epa.gov/international-cooperation/minamata-convention-mercury>.
- Van Meerbeek B, Peumans M, Poitevin A, Mine A, Van Ende A, Neves A, De Munck J. 2010. Relationship between bond-strength tests and clinical outcomes. *Dent Mater*. 26(2):e100–e121.
- Wambier DS, dos Santos FA, Guedes-Pinto AC, Jaeger RG, Simionato MR. 2007. Ultrastructural and microbiological analysis of the dentin layers affected by caries lesions in primary molars treated by minimal intervention. *Pediatr Dent*. 29(3):228–234.
- Whitworth JM, Myers PM, Smith J, Walls AW, McCabe JF. 2005. Endodontic complications after plastic restorations in general practice. *Int Endod J*. 38(6):409–416.
- Yoshiyama M, Tay FR, Doi J, Nishitani Y, Yamada T, Itou K, Carvalho RM, Nakajima M, Pashley DH. 2002. Bonding of self-etch and total-etch adhesives to carious dentin. *J Dent Res*. 81(8):556–560.